

**STRUCTURAL CHANGES IN THE GERM EPITHELIUM OF JUVENILE RAT TESTICLES
AFTER DL-THYROXINE TREATMENT**

NADA STOŠIĆ-BOGDANOVIĆ and ANITA RADOVANOVIĆ

*Department of Histology and Embriology, Faculty of Veterinary Medicine, Bulevar JNA 18,
Belgrade, Yugoslavia*

(Received, 9. September 1993)

The aim of these investigations was to determine the specificity of the response of testicle germ epithelium after application of DL-thyroxine to male rats at the critical period of brain development and maturation when the brain was thyrosensitive. These experiments were performed with juvenile Albert Oxford rats in which hypothyroidism had been induced by injection of DL-thyroxine in doses of 150 µg per animal, from day 9 to 30 of postnatale life. The structure and cytological properties of testicle germ epithelium were analysed by light microscopy. The isolated testicles were weighed, fixed in Bouin's solution and stained with Weigert hematoxylin - eosin. The realtive frequency of cell associations of the germ epithelium was determined on cross sections of the seminiferous tubules. For cytological analyses of germinal cells the sections of tubules were fixed in 4% glutaraldehyde and postfixied in 1% OsO₄ and embedded in epon or araldite. Semithin sections were stained with methylene blue. The present study showed that DL-thyroxine treatment at a critical postnatal period of brain development and maturation impaired the normal growth of animals and testicles and at the same time retarded the first normal spermatogenesis. Abnormal changes were demonstrated at the level of the testicle germ epithelium, accompanied by fine cellular alteration in the pachytene spermatocytes. The number of seminiferous tubules which contained zygotene spermatocytes were increased ($p < 0.001$), but the number of tubules with more differented germ epithelium cells-spermatids were significantly reduced ($p < 0.001$).

Key words: Testicles, DL-thyroxine, juvenile rats

INTRODUCTION

It is evident that prenatal and postnatal distortion of thyroid hormones has a great influence on the development of neuroendocrine mechanisms i.e. maturation of hypothalamic mechanisms included in the control of thyroid gland

activity and the reproductive organs. Administration of DL-thyroxine (T₄) from 3 to 18 days during the postnatal period provoked caryopycnosis and degeneration of neurosecretory cells in paraventricular (PVN) and ventromedial (VMN) hypothalamic nuclei (Stošić, 1980) and secretion of follitropin (FSH) and prolactin (PRL) (Schneider et al., 1979; Sawers et al., 1982). Hypothyroidism of pregnant and lactating dams delays the appearance of the first wave of spermatogenesis in the testicles of rat pups and caused alterations of the Sertoli cells and degeneration of spermatocytes (Stošić and Radovanović, 1992). Our earlier data, also indicated the important function of the thyroid gland in maintaining the function of certain hypothalamic nuclei and the synthesis of STH, PRL, TSH and GTH hormones and their release in mature rats (Stošić et al., 1969, 1981, 1990). It is well known that thyroid hormones are important for postnatal development and maturation of the CNS. The rat brain is thyreosensitive from postnatal day 9 to 14. During this period differentiation of nerve cells and multiplication of glia cells, prepared for myelinization, occur. Microneurons are still present (Nicholson and Altman, 1972, Tsukada et al., 1977).

Hawing in mind the fore mentioned the intention of the present study was induction of rat hypothyroidism by application of high doses of T₄ from day 9 of postnatal life, i.e. during the period when the rat brain is thyreosensitive. We monitored body and testicles mass, as well as cytological manifestations in the germ epithelium of 30 day old rats.

MATERIAL AND METHODS

For this study we used 20 Albert Oxford (AO) male rats, 9 days old at the beginning of the experiments. The rats were kept under controlled conditions of nutrition, temperature and humidity. The 9 day old animals were treated, every other day, with DL-thyroxine (Roche), in doses of 150 µg per animal, up to the 30th postnatal day. Infact and treated 30 day old rats were sacrificed. Isolated testicles were weighed and fixed in Bouin's solution and stained with Weigert hematoxylin-eosin and azan. The relative frequency of cell associations of the germ epithelium was determined on cross sections of the seminiferous tubules. Pieces of testicles were fixed in 4% glutaraldehyde in Miloniq buffer and postfixed in Miloniq-buffered 1% O₃O₄ and embedded in epon or araldite. Semithin sections, 1 µm thick, were stained with methylene blue and examined using a light microscope. The parameter of the changes in the germ epithelium was the number of tubules with zygotene and pachytene spermatocytes, as well as spermatids, which was established by analysing one cross-section of the testicles. Body and testicles mass as well as the number of different cell populations in the germ epithelium, were statistically analysed using Student's-t-test.

RESULTS

Body mass and absolute testicle mass were depressed in thyroxinized 30 day old rats. The decline was significant for body and testicles mass ($p < 0.001$).

Table 1. Body and testicles mass of infact and thyroxine treated rats (DL-T₄).

Tissue	I	DL-T ₄
Body mass (g)	51.86±0.55	43.40±1.80 + + +
Testicular mass (mg)	470.44±10.08	207.86±4.94 + + +

Values are mean ±SE

+ + + significantly different ($p < 0.001$)

In the testicles of 30 day old intact rats the seminiferous tubules were composed of Sertoli cells, premeiotic and postmeiotic forms and early spermatids. These cellular associations correspond to successive stages of the spermatogenic cycle in adult rats. In a great number of seminiferous tubules, the germ cells were in the period of development and maturation and frequent divisions were observed. In some seminiferous tubules spermatogonia of II generation were hypertrophic with light nuclei and diffusely distributed chromatin (Figure 1A). About 28 ± 3.36 tubules contained zygotene and 112 ± 12.67 pachytene spermatocytes. The most differentiated cells of the first generation of spermatogenesis were spermatids and 63.3 ± 4.65 tubules contained spermatids (Figure 2).

Histological and cytological analysis showed that in juvenile rats DL-thyroxine treatment led to a sequential degree of changes in the testicles. In the germ epithelium derangement of cells, pycnosis and degeneration of pachytene spermatocytes was observed. In the tubules ghost spermatocytes with cytoplasmic remnants and no nuclear material were noticed. Some pachytene spermatocytic nuclei were small and poor in chromatin. In the Sertoli cells numerous dense lipid drops were evidenced (Figures 1B,C). The assessment of the various cell types in the intact and treated groups of rats are shown in Figure 2. A significant increase in the number of tubules which contain zygotene spermatocytes- 110.2 ± 8.04 ($p < 0.001$) I and a markedly reduced number of tubules with early spermatids- 18.8 ± 1.66 ($p < 0.001$) were noted.

DISCUSSION

Since thyroid hormones are important for development of the CNS, in these experiments male rats, were treated with $150 \mu\text{g}$ of DL-T₄ from 9 to 30 days of postnatal life. The brain is thyrosensitive from 9 to 14 days after partus and the cerebellum of newborn rats is immature. The diencephalon develops before the cerebrum cortex and matures before the cerebellum (Davison et al., 1968). In the same period of postnatal life the thyroid hormones are responsible for the multiplication of glia cells and myelin formation (Amur et al., 1984). A disthyroid state induces metabolic and morphologic changes only in immature tissue while the brain of adult animals does not react to the changes of T₄ levels (Eyars et al, 1960). Large doses of T₄ in this period can influence the timing of cell proliferation and the onset of neuronal differentiation in the cerebellar cortex and has been found to be accompanied by a decrease in the final number of cells (Nicholson and Altman, 1972a). After DL-T₄ treatment of 3 day

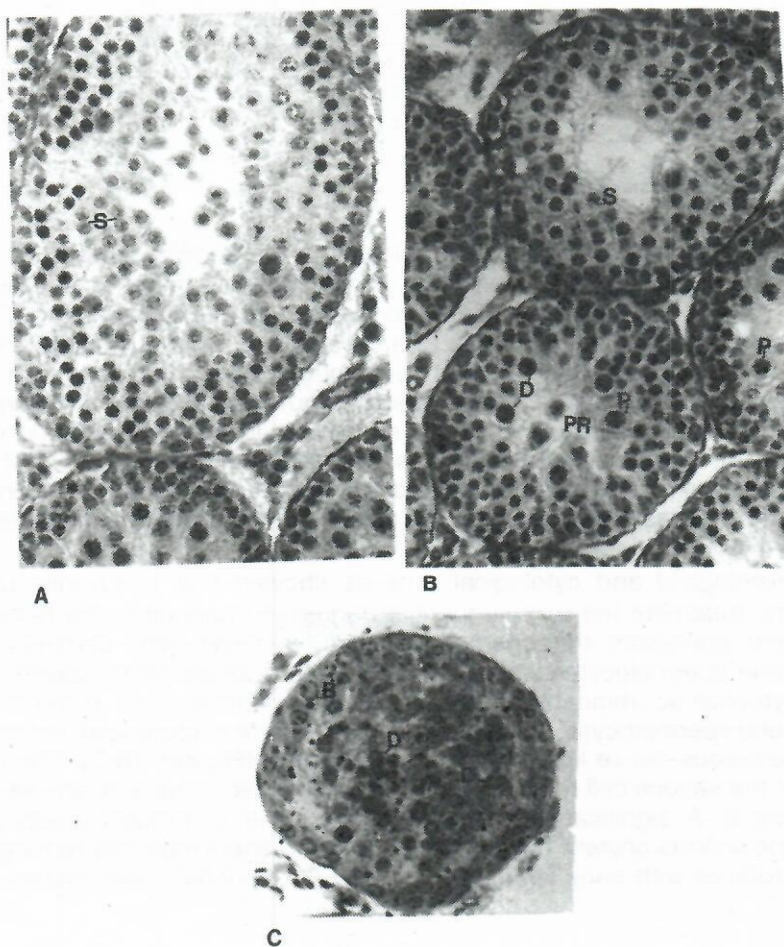


Figure 1. Germ epithelium of intact 30 day old rats (A) and rats treated with DL-thyroxine (B,C). Bouin. Hematoxylin-eosin.x516 (A,B); 4% Glutaraldehyde and 1% O_3O_4 Methylene blue. x 900.

B - B spermatogonia; Z - zygotene spermatocytes; P - pachytene spermatocytes;
Pr - cytoplasmic remnants of pachytene spermatocytes; S - spermatids;
D - germ cells in regression.

old male rats, in a dose of 50 μ g per animal, every other day, up to the age 13 or 18 days, changes the diencephalon were observed. A reduction in the nuclear volume of hypothalamic paraventricular (PVN) and ventromedial (VMN) cell nuclei and inhibition of neurosecretion from the neurosecretory cells were detected. When DL- T_4 was injected over the 22 to 32 day of postnatal period the above mentioned structural shapes were clearly pronounced and nuclear pycnosis and cytoysis of neurosecretory cells were noticeable (Stošić, 1980).

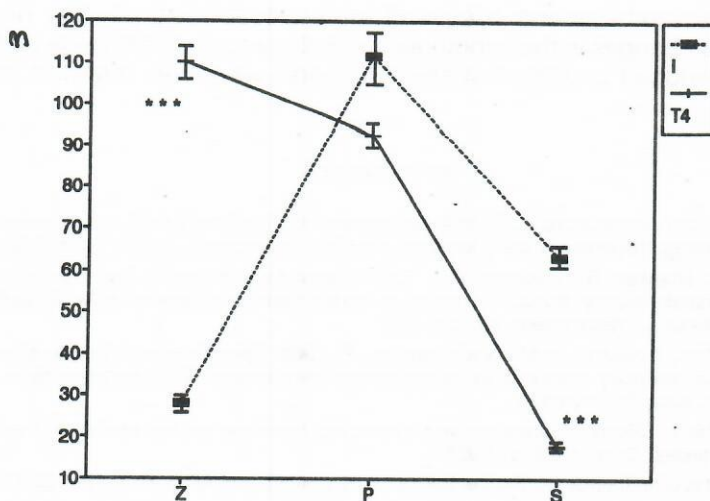


Figure 2. The spectrum of zygote spermatocytes (Z), pachytene spermatocytes (P) and spermatids (S) in the seminiferous tubules.
(Expressed as mean values \pm SEM, +++ - significantly different/ $p < 0.001$)

The long term effect of T_4 increased gonadotropic levels in the rabbit pituitary, which was probably the result of inhibition of the release of these hormones into the circulation (Aleshin and Bondarenko, 1983). Schneider et al., (1979) suggested that T_4 decreases FSH concentration in rat serum via direct suppression of FSH cell activity or via acceleration of FSH cell metabolism. A low level of gonadotropic hormones induced regressive changes in the germ epithelium which resulted in retardation of spermatogenesis. Hypothyroidism of 40 day old rats changed the level of LH, PRL and testosterone in serum which suggests that thyroid hormones have a modulatory effect on the testicles, i. e. LH dependent secretion of testosterone (Vale et al., 1985.) According to Aruldasu et al. (1984), T_4 directly affects enzymes involved in carbohydrate and lipid metabolism in the testicles. Thyroxine specifically affected pyruvate kinase activity, especially in prepubertal and pubertal life and directly regulated the pentophosphate way. Prolactin increased the sensitivity of testicles to LH during normal sexual maturity. It is well known that PRL affects storage of esterified cholesterol and the activity of 3 beta- and 17 beta-hydroxysteroid dehydrogenases in mouse testicles (Barthe, 1971, Musto et al., 1972). Thyroid hormones inhibited PRL secretion (Sawers et al., 1982). Richards et al. (1980) reported that dopamine and noradrenaline exert direct inhibitory effects on PRL secretion in the pituitary. On the other hand certain concentrations of 5 HT (serotonin) in the plasma stimulated production and/or secretion of a complete biologically active form of LH (Sawcenko et al., 1983).

On the basis of our previous studies and the cited data about the effects of thyroid hormones on the hypothalamo - pituitary system, we suggest that application of high doses of DL- T_4 caused lower basal secretion of liberines

and lower biosynthesis and release of the corresponding pituitary hormones. As a result of changes in the hypothalamo-pituitary system, the body and testicle mass was reduced and the first spermatogenic wave was retarded in 30 day old rats.

REFERENCES

1. Aleshin, B.V. and Bondarenko, L.A. 1984. Rolj gormona ščitovidnoj železi v funkcionirovani sistem gipofiz nadpoččenki-gonadi u krolikov. *Problem. Endocrinol. (Mosk)*. 30, 49-52.
2. Amur, S.G., Shanker, G., Pifringer, R.A. 1984. Regulation of myelin basic protein (arginine) methyltransferase by thyroid hormone in myelinogenic cultures of cells dissociated from mouse brain. *J. Neurochem.* 43, 494-498.
3. Aruldas, M.M., Volivullah, H.M., Govindarajulu, P. 1984. Specific effect of thyroid hormone on testicular enzymes involved in carbohydrate metabolism. 2 Hyperthyroidism. *Biochem. Biophys. Acta* 715, 121-125.
4. Bartke, A. 1971. Effects of prolactin and luteinizing hormone on the cholesterol stores in the mouse testes. *Steroid*. 23, 921-928.
5. Eyars, J.T. 1960. Influence on the central nervous system. *Brit Med. Bull.* 16, 122-126.
6. Davison, A.N. and Dobbing, J. 1968. The developing brain, pp. 253-286. and 287-316. In: "Applied Neurochemistry". A. N. Davison and Dobbing (Eds). Black well, Oxford.
7. Musto, N., Hafes, A.A. and Bartke, A. 1972. Prolactin increases 17 beta-hydroxysteroid dehydrogenase activity in the testis. *Endocrinol.* 91, 1106-1108.
8. Nicholson, I.L. and Altman, I. 1972a. The effects of early hypo- and hyperthyroidism on the development of rat cerebellar cortex. I Cell proliferation and differentiation. *Brain. Res.* 44, 13-23.
9. Richards, G.E., Holland, F.J. Auberts, M.L., Ganong, W.F., Kaplan, S.L. and Grumbach, M.M. 1980. Regulation of prolactin and growth hormone secretion. STH and mechanism of action of thyrotropin-releasing hormone, L-dopa and L-5-hydroxytryptophan in unanesthetized dogs. *Neuroendocrinol.* 30, 139-143.
10. Savers, I.S.A., Kellett, H.A., Brown, N.S. Seth, J. and Toft, A.D. 1982. Prolactin response to metochlopramide in hyperthyroidism. *J. Clin. Endocrinol. and Metab.* 55, 175-177.
11. Sawchenko, D.E. Swanson, L.W., Steinbusch, H.W.M. and Verhoofstad, A.A.J. 1983. The distribution and cells of origin of serotonergic inputs of the paraventricular and supraoptic nuclei of the rat. *Brain Research.* 277, 355-360.
12. Stošić, N., Pantić, V., Pavlović-Hournac, M. and Radovanović, D. 1969. Systeme hypothalamo-hypophysaire des rats thyroidectomises porteurs de greffes intraoculaires de thyroïde. *Z. Zellforsch.* 102, 554-569.
13. Stošić, N. 1980. The effect of thyroxine on some hypothalamic nuclei, pituitary cells producing glycoprotein hormones and spermatogenesis of immature rats. *Jugoslav. Physiol. Pharmacol. Acta.* 16, 209-220.
14. Stošić, N., Kilibarda, M., Lovren, M. 1981. The pituitary cells of thyroidectomized and thyroxine treated infact and thyroidectomized mature rats. *Jugoslav. Physiol. Pharmacol. Acta.* 17, 31-39.
15. Stošić, N., Gledić, D., Radovanović, A. 1990. The pituitary cells of infantile rats after thyroxine treatment. *Acta Veterin.* 40, 173-182.
16. Stošić-Bogdanović, N. and Radovanović, A. 1992. The effect of hypothyroidism in pregnant and lactating dams on the testicles of juvenile pups. *Acta Veterin.* 42, 99-108.
17. Schneider, G., Kopach, K., Onanian, H., Bonnefond, V., Mittler, J. and Ertel, N. 1979. The hypothalamo-pituitary-gonadal axis during hyperthyroidism in the rat. *Endocrinol.* 105, 674-679.
18. Tsukada, Y., Nomura, M., Nigai, K., Kohasaka, S., Kawahata, H., Ito, M., Matsutani, T. 1977. Neurochemical correlates of learning ability. In: Behavioral neurochemistry. Delgado, J. N. R., De Feudis, F. V. (Eds). 63-84. (Spectrum New York, 1977).

19. Valle, L.B.S., Oliverira-Filo, R.M., Romaldini, J.H. Lara, P.F. 1985. Pituitary-testicular axis abnormalities in immature male hypothyroid rats. *Steroid. Biochem.* 23, 253-258.

PROMENA STRUKTURE GERMINATIVNOG EPITELA SEMENIKA JUVENILNIH PACOVA TRETIRANIH DL - TIROKSINOM

NADA STOŠIĆ-BOGDANOVIĆ I ANITA RADOVANOVIĆ

SADRŽAJ

Namera ovog rada je ispitivanje specifičnog odgovora germinativnog epitela semenika posle aplikacije DL-tiroksina pacovima, mužjacima, u toku kritičnog perioda razvoja i sazrevanja mozga, odnosno, osetljivosti mozga na tiroksin. Eksperimenti su izvođeni sa juvenilnim pacovima, Albert Oxford (A.O.) rase, kod kojih je hipotireoidizam indukovao aplikovanjem DL - tiroksina, u dozi od 150 μ g na životinju, od 9 do 30 dana postnatalnog života. Struktura i citološke odlike germinativnog epitela semenika su analizirane svetlosnim mikroskopom. Izolovani semenici su mereni, fiksirani u Bouiovom rastvoru i bojeni Weigertovim hematoksilinom i eozinom. Relativna frekvenca asocijacija ćelija germinativnog epitela je određivana na poprečnim presecima semenih kanalića. Za citološke analize germinativnih ćelija isecci semenih kanalića su fiksirani u 4% glutaraldehidu, dofixirani u 1% O_3O_4 i uklapani u eponu i aralditu. Polutanki preseci su bojeni metilenskim plavim.

Rezultati ispitivanja ukazuju da tretiranje DL-tiroksinom u toku kritičnog postnatalnog perioda razvoja i sazrevanja mozga menja normalan razvoj pacova i semenika sa istovremenim usporavanjem prve normalne spermatogeneze. Promenjena struktura germinativnog epitela semenike je praćena citološkim promenama pahitenih spermatocita. Broj semenih kanalića koji sadrže zigotene spermatocite je uvećan ($p < 0.001$), značajno je smanjen broj kanalića sa najdiferentovanijim ćelijama germinativnog epitela - spermatidama ($p < 0.001$).

